

Figure 1
Protozoa Found in Stool Specimens of Humans: Amebae

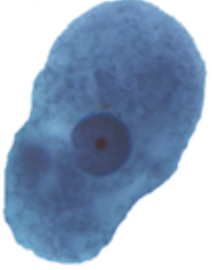

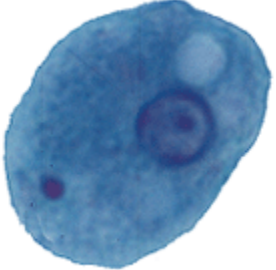
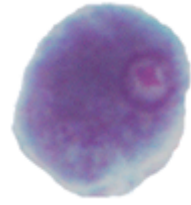



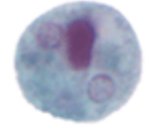
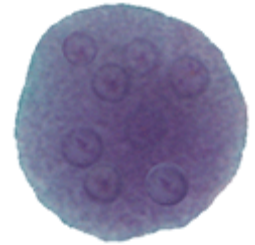
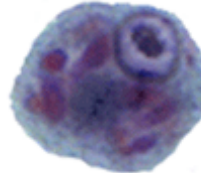











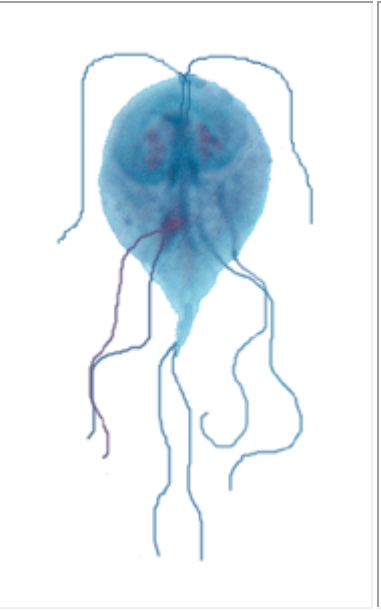


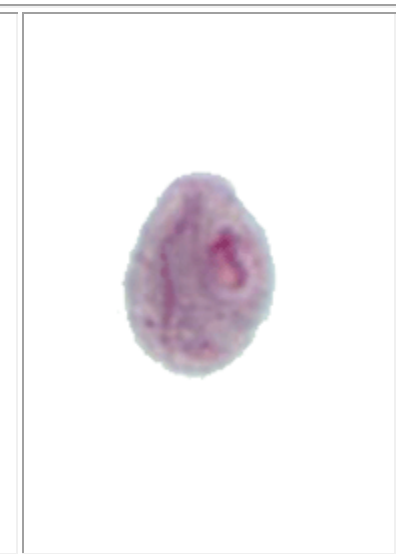

| Amebae | | | | | | |
|-------------|--|--|---|--|--|--|
| | <i>Entamoeba histolytica/dispar</i> | <i>Entamoeba hartmanni</i> | <i>Entamoeba coli</i> | <i>Entamoeba polecki</i> | <i>Endolimax nana</i> | <i>Iodamoeba beutschlii</i> |
| Trophozoite |  |  |  |  |  |  |
| Cyst |  |  |  |  |  |  |
| |  |  |  |  |  |  |
| Scale |  10 μ m | | | | | |

Figure 2
Protozoa Found in Stool Specimens of Humans: Ciliate and Flagellates

| | Ciliate | Flagellates | | |
|--------------------|---|---|---|--|
| | <i>Balantidium coli</i> | <i>Chilomastix mesnili</i> | <i>Giardia intestinalis</i> | <i>Dientamoeba fragilis</i> |
| Trophozoite |  A large, pear-shaped trophozoite of Balantidium coli with a thick, ciliated outer layer and a distinct nucleus. |  A pear-shaped trophozoite of Chilomastix mesnili with a prominent nucleus and several long flagella extending from the anterior end. |  A pear-shaped trophozoite of Giardia intestinalis with a pear-shaped body, a large nucleus, and several flagella. |  A small, circular trophozoite of Dientamoeba fragilis with a pinkish-red color and a few flagella. |
| Cyst |  A large, spherical cyst of Balantidium coli with a thick, multi-layered wall and a granular interior. |  A small, oval-shaped cyst of Chilomastix mesnili with a thick wall and a central nucleus. |  A pear-shaped cyst of Giardia intestinalis with a thick wall and a central nucleus. | no cyst stage |


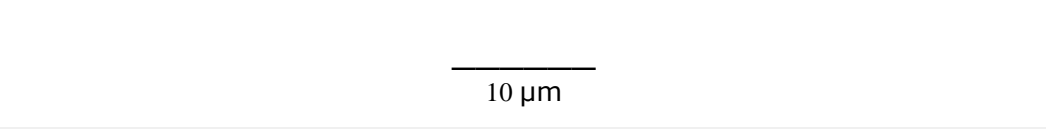



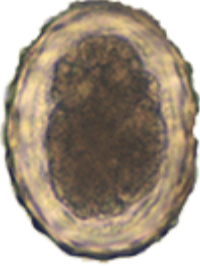








| | | | | |
|--------------|--|---|--|--|
| | |  |  | |
| Scale |  <p>40 μm</p> |  <p>10 μm</p> | | |

Figure 4
Nematode and Cestode Eggs Found in Stool Specimens of Humans









| Nematodes | | | | | | |
|---|---|---|---|---|---|---|
|  |  |  |  |  |  |  |
| <i>Capillaria philippinensis</i> | <i>Enterobius vermicularis</i> | <i>Trichuris trichiura</i> | <i>Ascaris lumbricoides</i> fertile | <i>Ascaris lumbricoides</i> infertile | Hookworm | <i>Trichostrongylus</i> spp. |

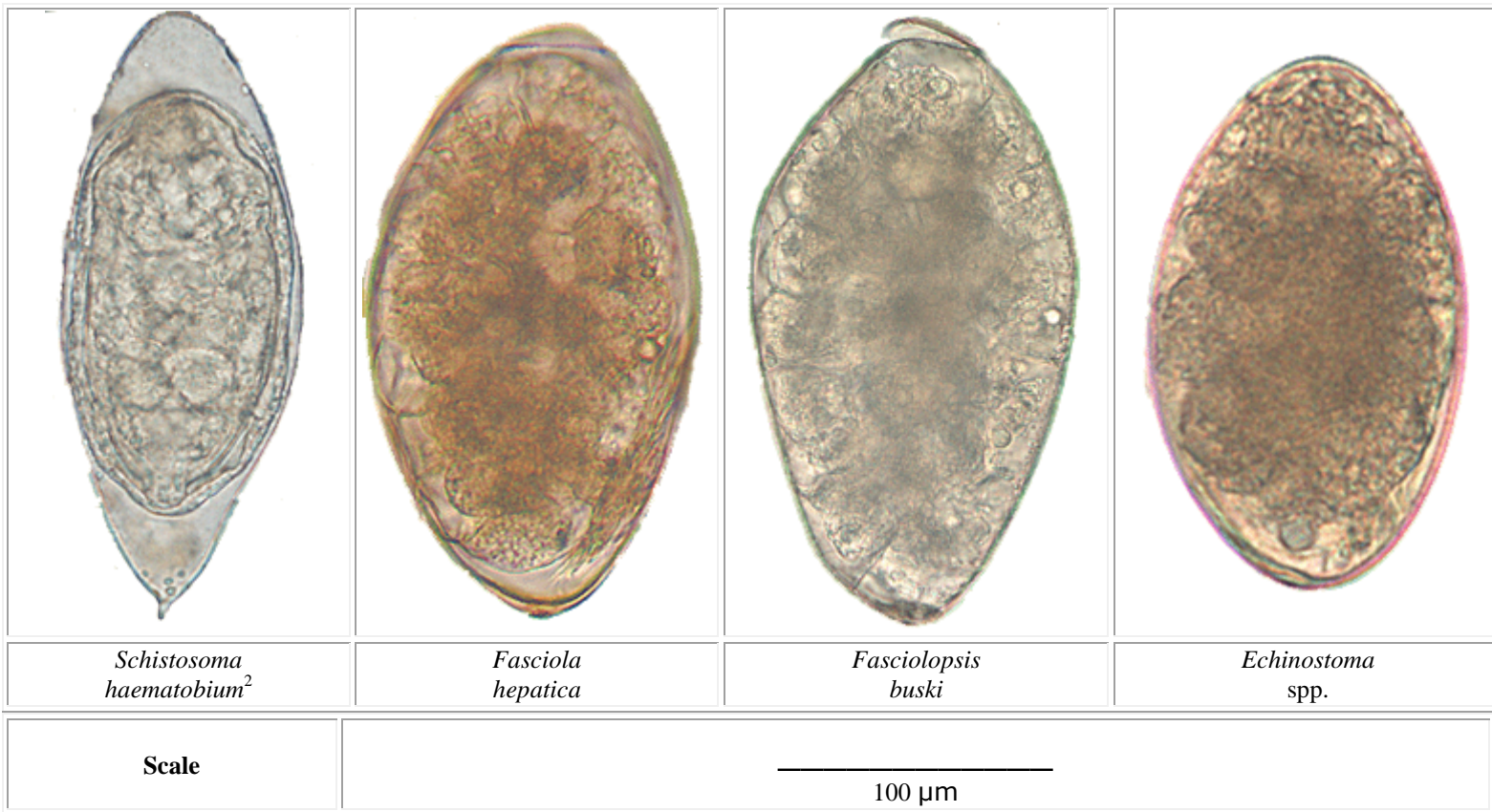
| Cestodes | | | | |
|---|---|---|--|--|
|  |  |  |  |  |
| <i>Taenia</i> spp. | <i>Hymenolepis nana</i> | <i>Hymenolepis diminuta</i> | <i>Diphyllobothrium latum</i> | <i>Dipylidium caninum</i> |

Scale

50 μm

Figure 5
Trematode Eggs Found in Stool Specimens of Humans

| Trematodes | | | |
|--|--|---|--|
|  |  |  |  |
| <i>Clonorchis sinensis</i> | <i>Opisthorchis viverrini</i> | <i>Paragonimus westermani</i> ¹ | <i>Nanophyetus salmincola</i> |
|  |  |  |  |
| <i>Schistosoma japonicum</i> | <i>Schistosoma mekongi</i> | <i>Schistosoma mansoni</i> | <i>Schistosoma intercalatum</i> |



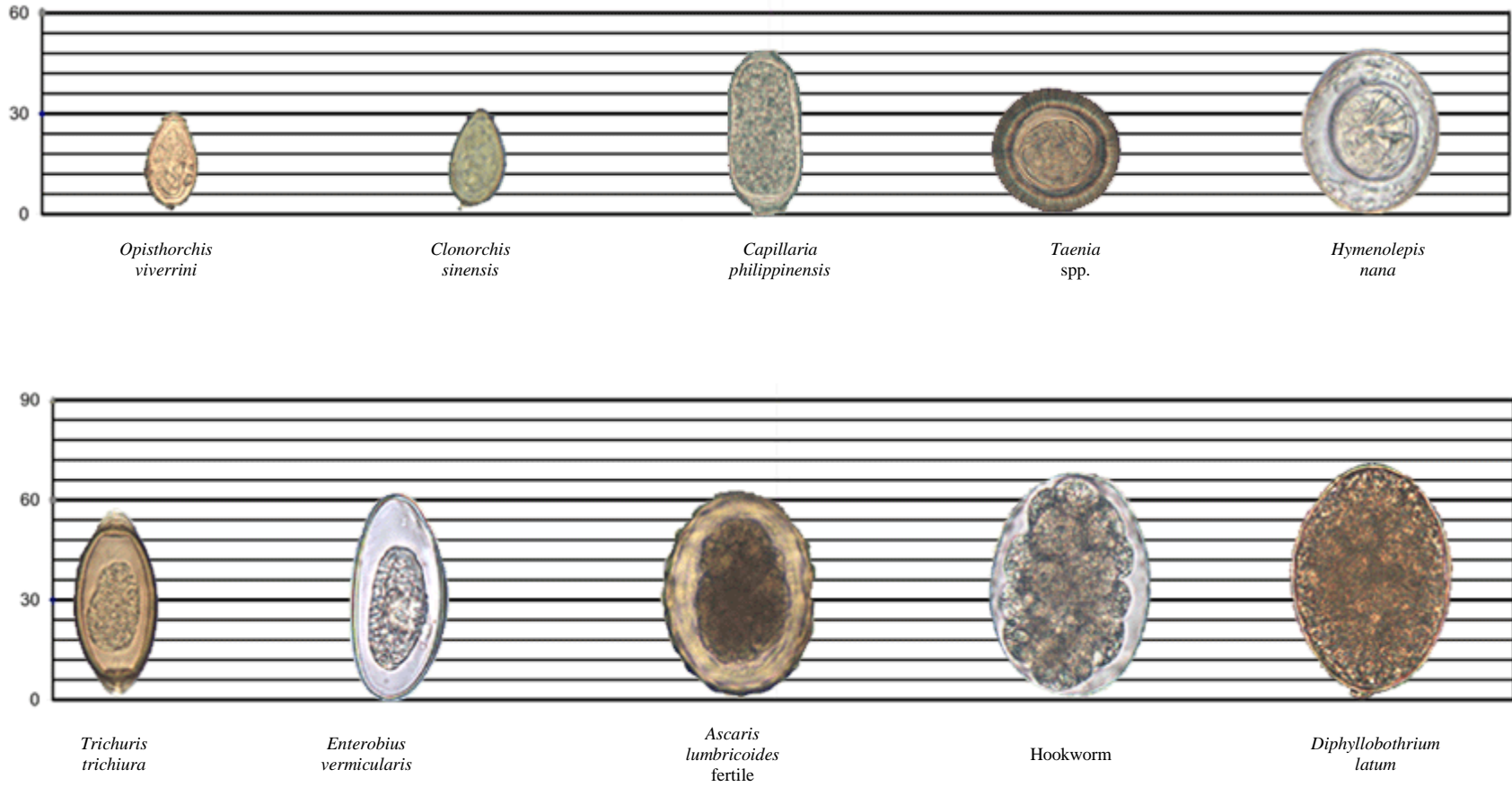
¹Usually found in respiratory specimens.

²Usually passed in urine.

Figure 6

Relative Sizes of Helminth Eggs

Measurements in micrometers (μm)





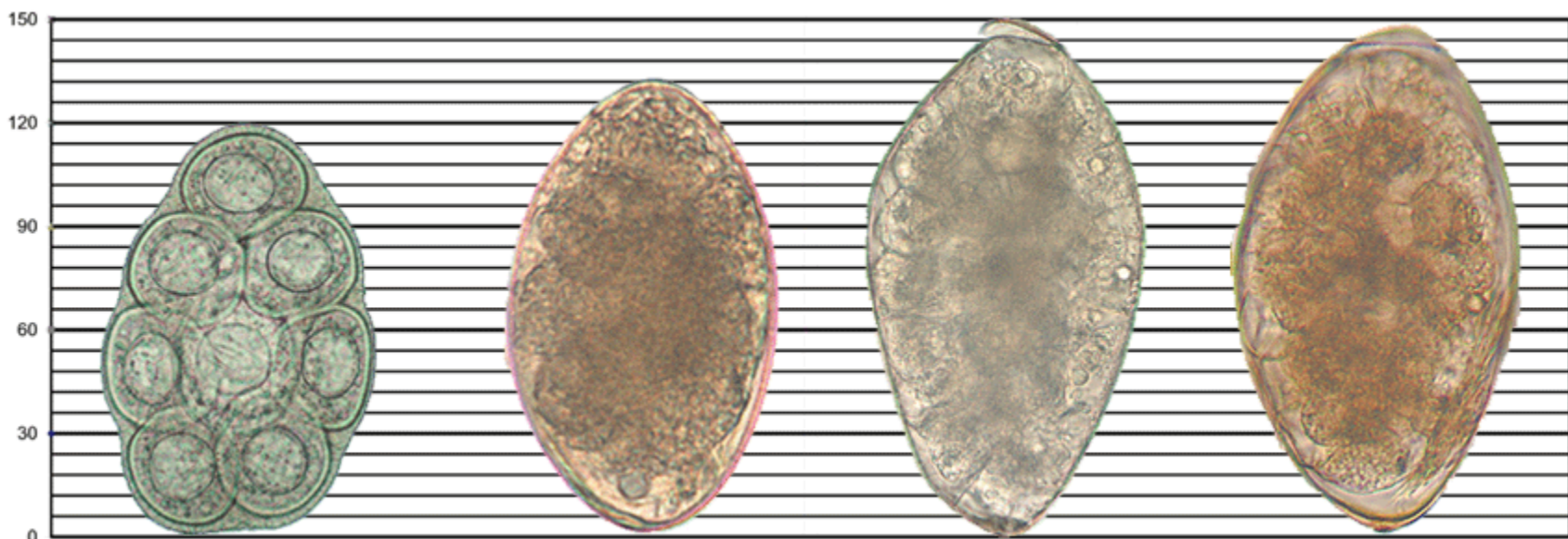
Hymenolepis diminuta

Trichostrongylus spp.

Nanophyetus salmincola

Paragonimus westermani

Ascaris lumbricoides infertile

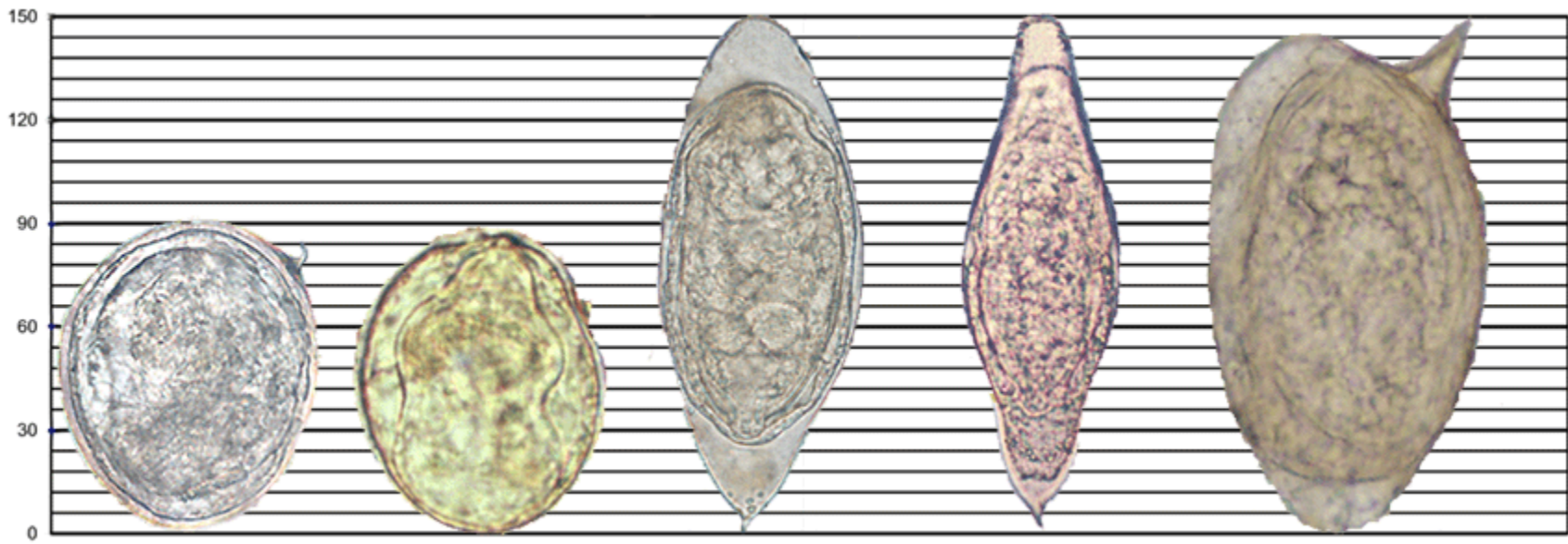


Dipylidium caninum

Echinostoma spp.

Fasciolopsis buski

Fasciola hepatica



Schistosoma japonicum

Schistosoma mekongi

Schistosoma haematobium

Schistosoma intercalatum

Schistosoma mansoni

Figure 7
Hookworm and *Strongyloides* Larvae

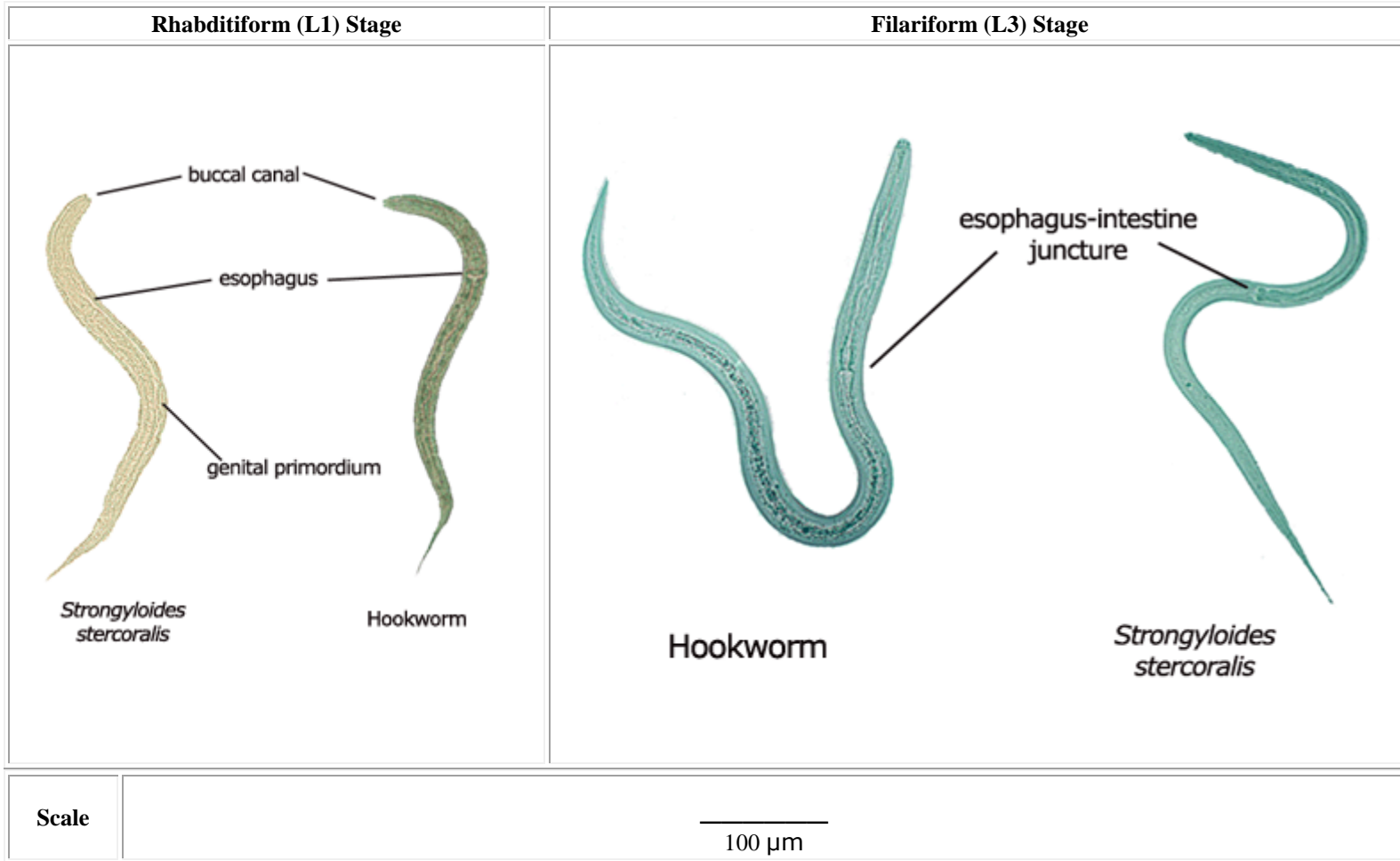
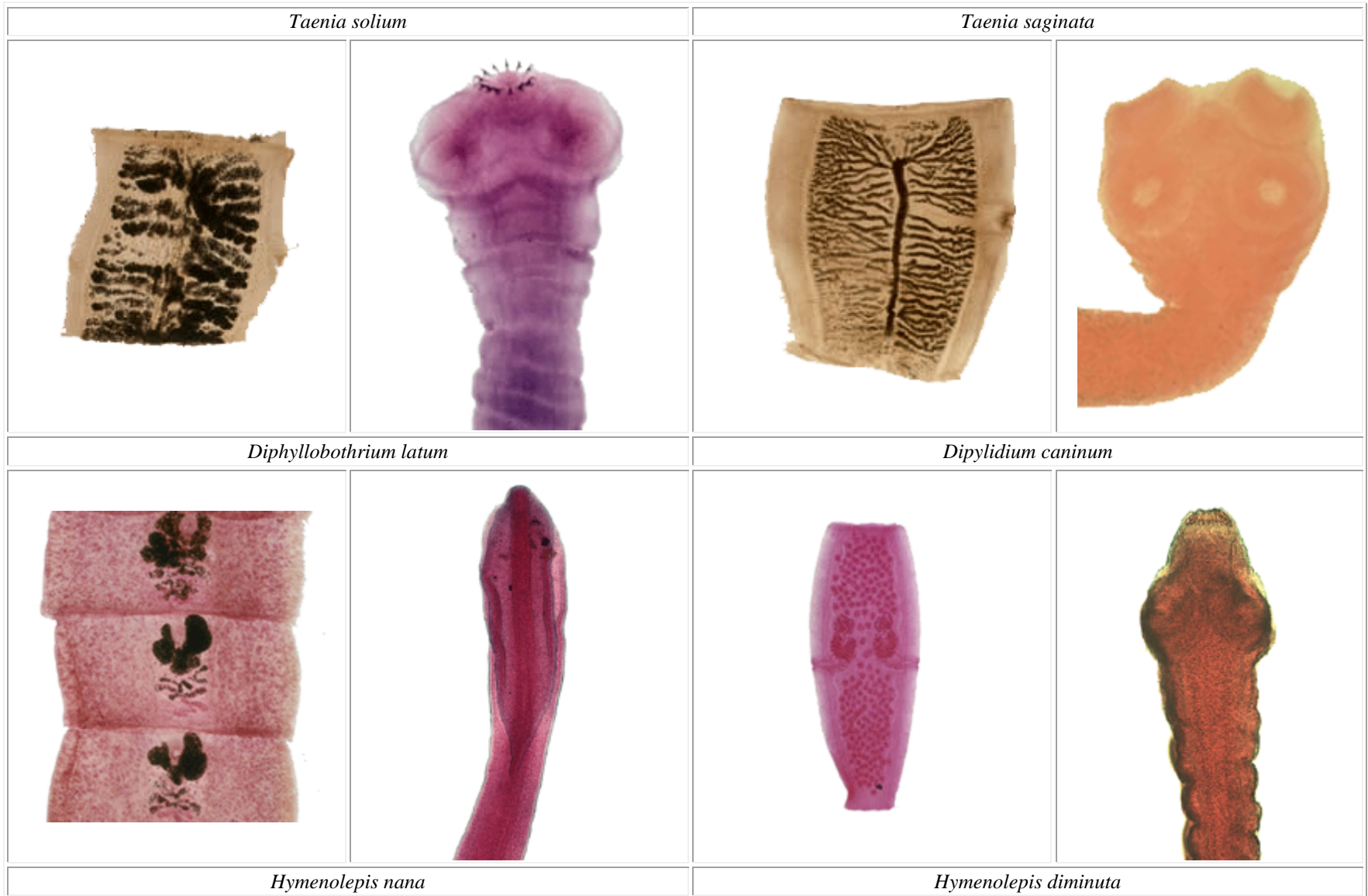


Figure 8
Gravid Proglottids and Scoleces of Cestode Parasites of Humans



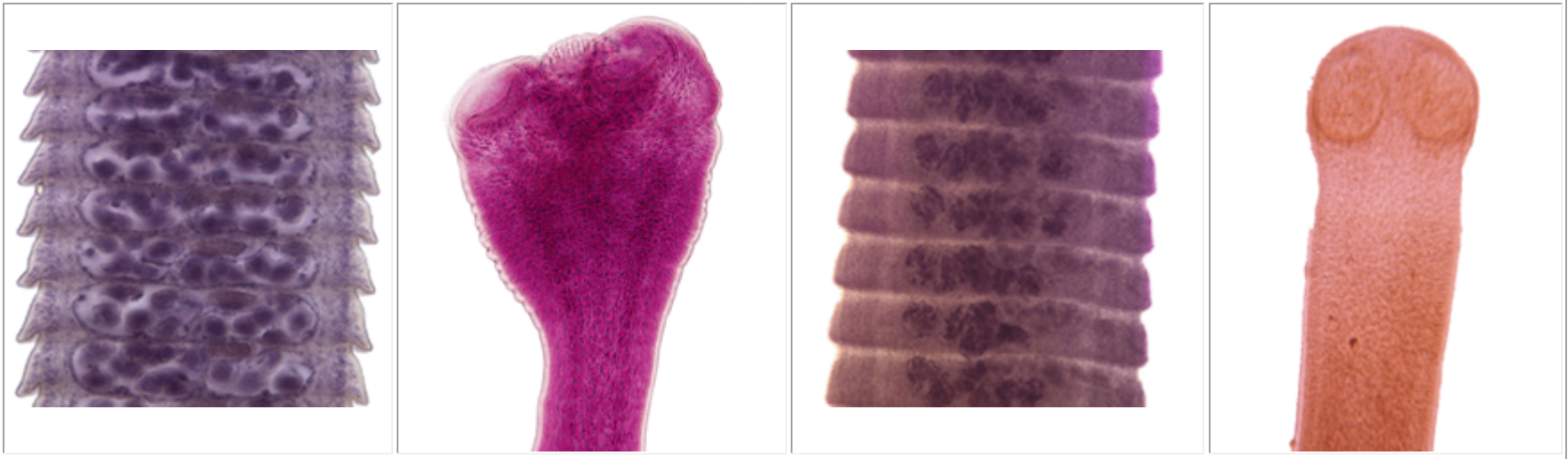
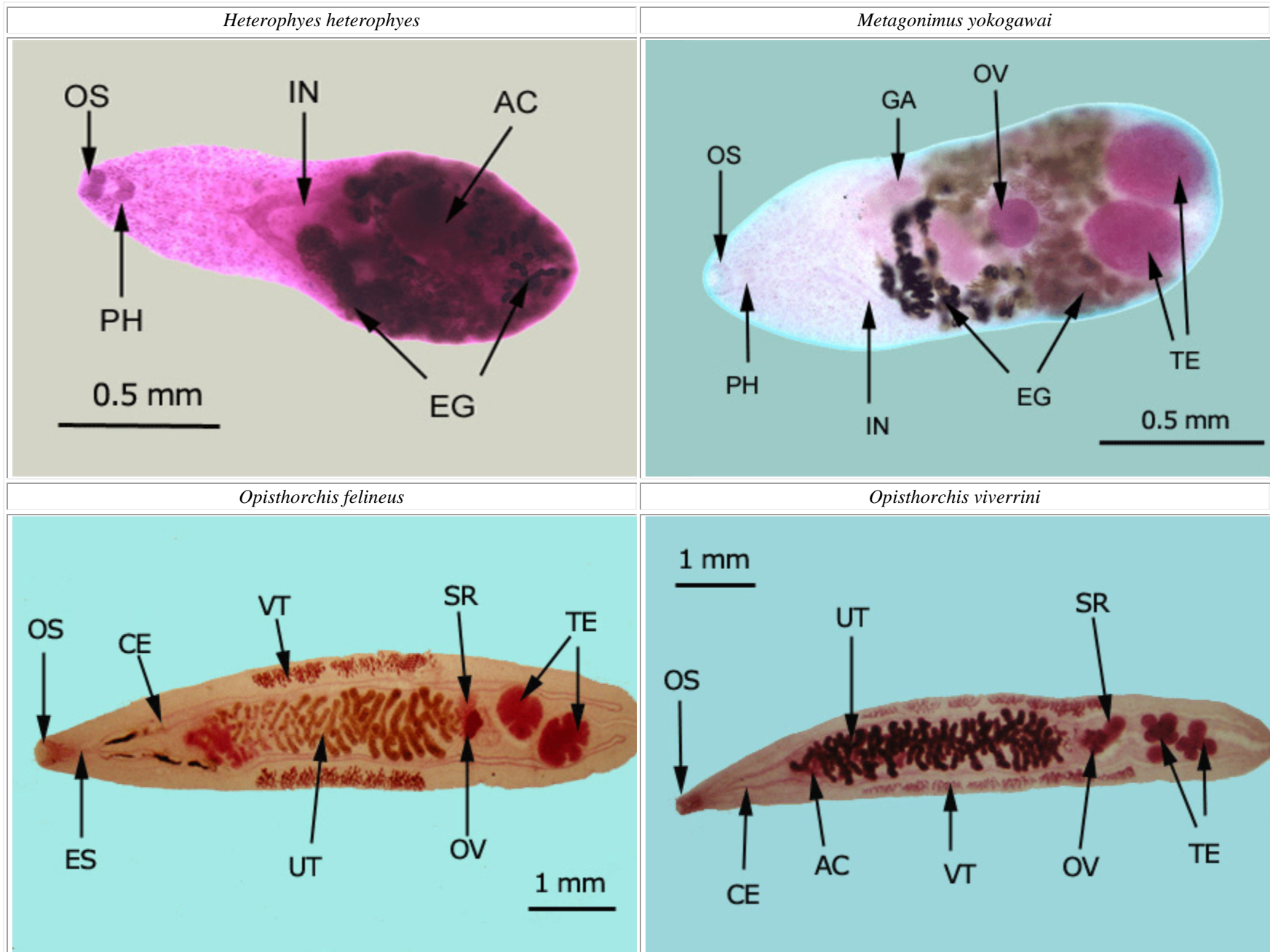
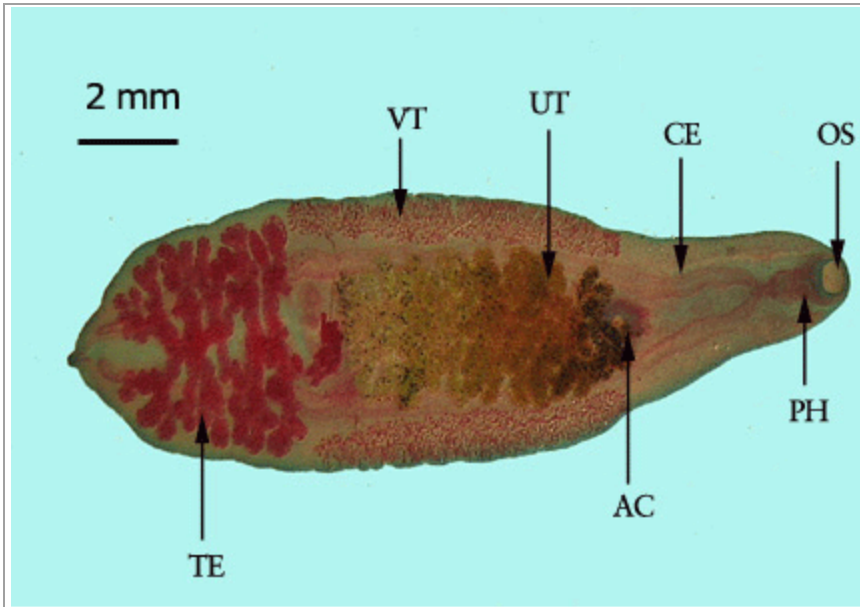


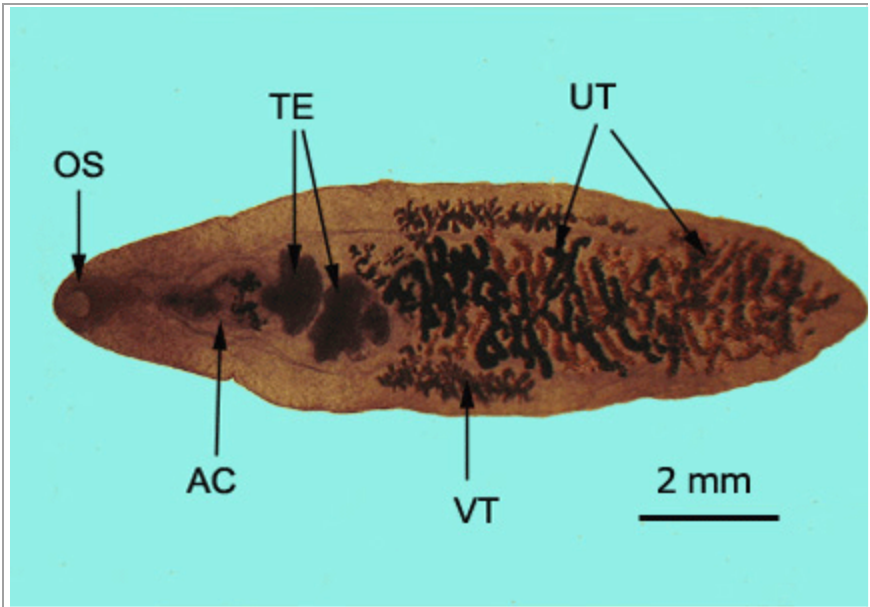
Figure 9
Adult Visceral Trematodes of Humans



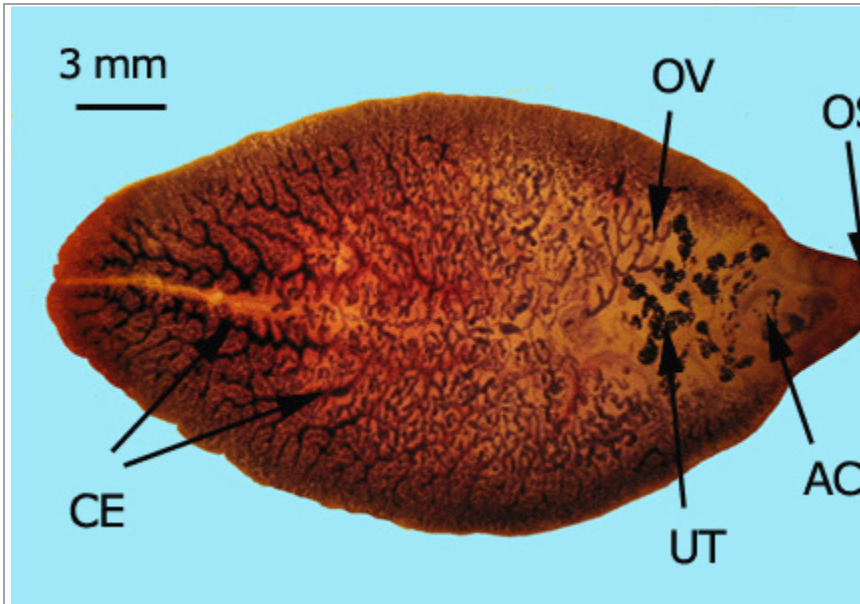
Clonorchis sinensis



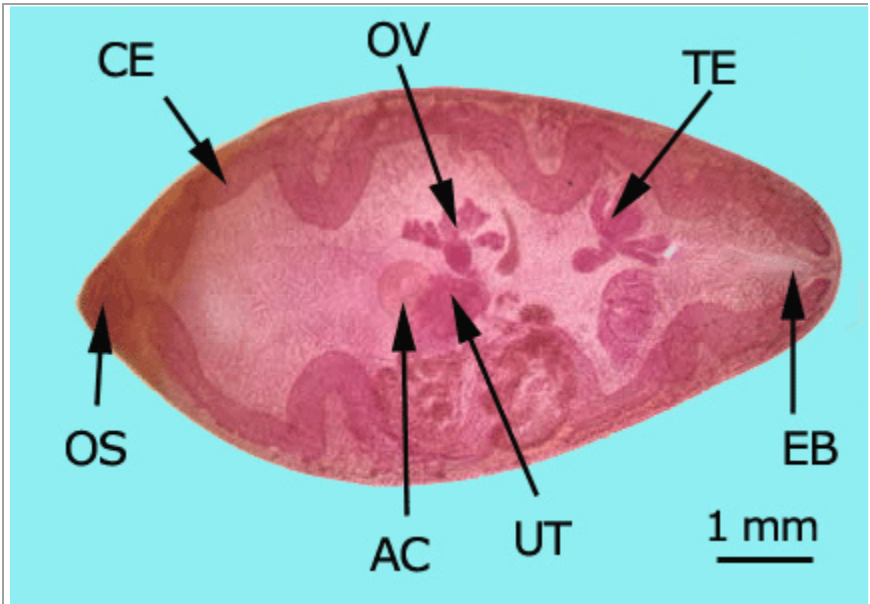
Dicrocoelium dendriticum



Fasciola hepatica



Paragonimus westermani



Echinostoma revolutum

